

Vol.11

Vol.11

50

IBD AS RA

RA

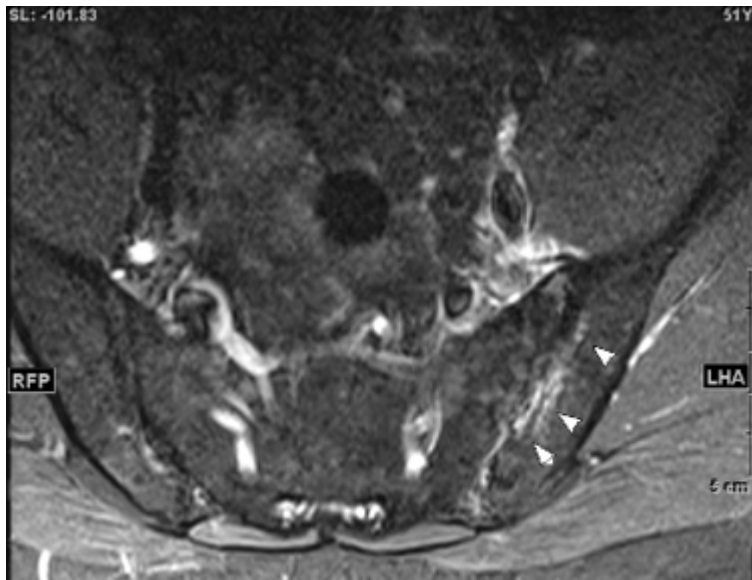
Psoriatic onycho-pachydermo periostitis:POPP X MRI a:T2FS, b:T2FS, c:T1 X

X PsA

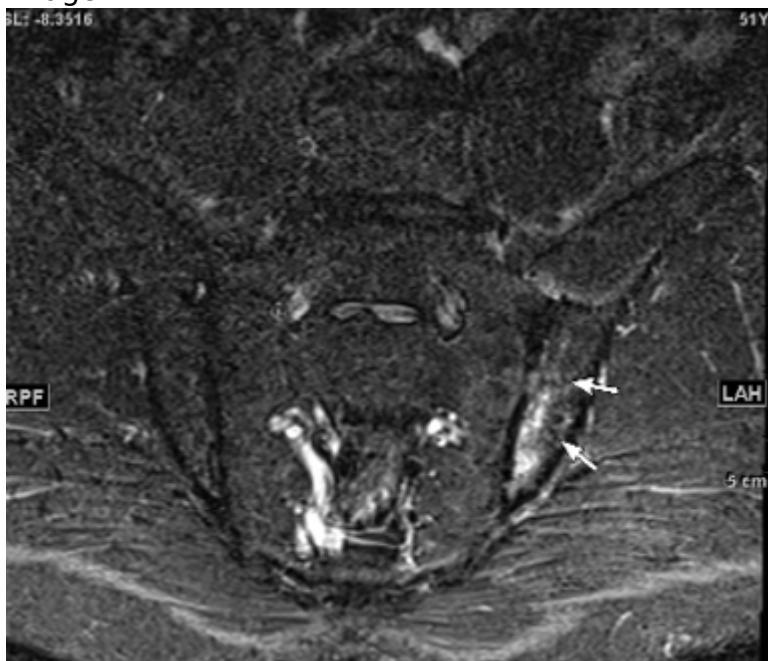ASAS/SPARTAN 2024 MRI 1.S2 T1 STIR or T2 T1 3D T1 STIR or T2

a,b,c MRI

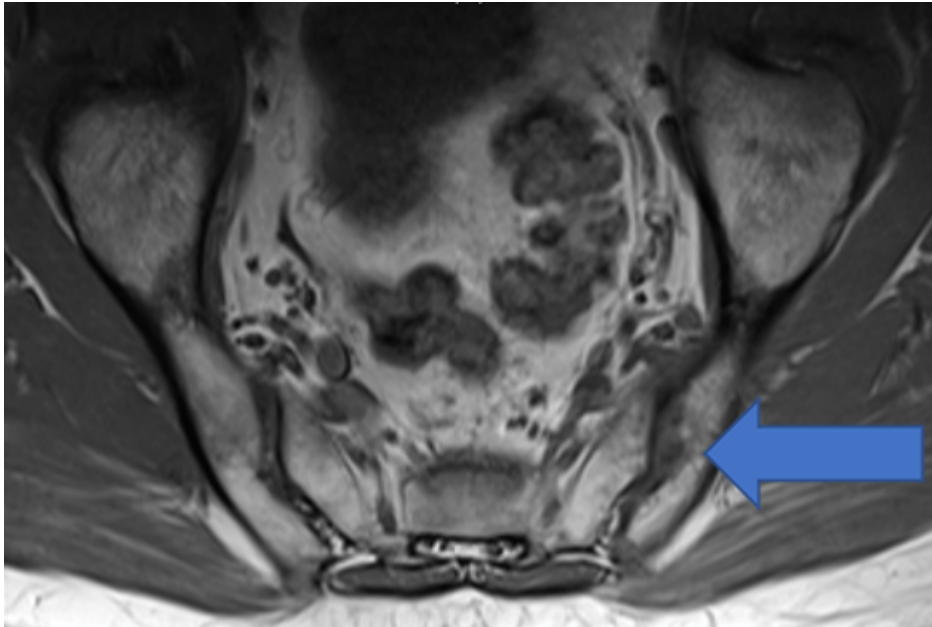
Image



Image



Image



Ann Rheum Dis. 2024 Aug 6:ard-2024-225882.

CTX00044JG0001
202412

[XXXXX](#)
[XXXXXXXXXX XXXXXXXX](#)

XXXXXXXXXXXXXXXXXXXX

[XXXXXX](#)

Source URL:

https://prod.pro.novartis.com/jp-ja/support/lecture/joint_finding/case011_answer_11